Anévrismes des artères rénales

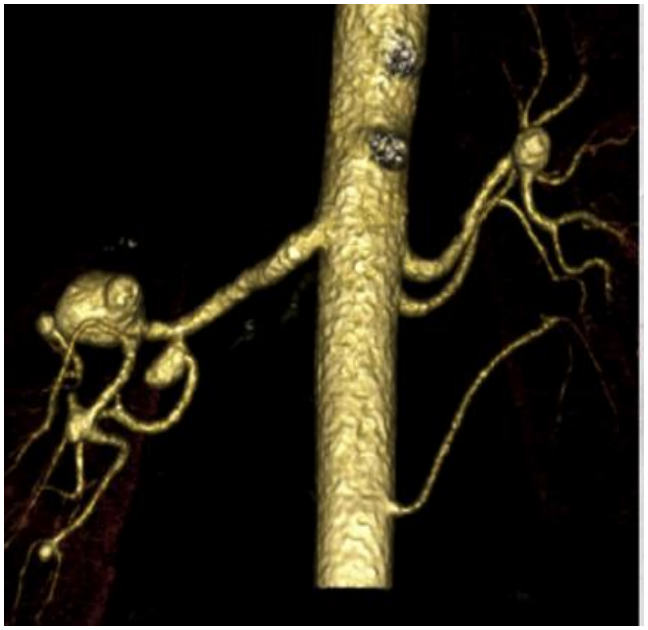

51ème Congrès du Collège Français de Pathologie Vasculaire

Dr JM Davaine

17 Mars 2017

HÔPITAUX UNIVERSITAIRES
PITIÉ SALPÊTRIÈRE - CHARLES FOIX

Pas de conflits d’intérêts

Introduction

« Dilatation focale, isolée des 3 feuillets artériels >1,5 fois le diamètre du vaisseau sain adjacent proximal »

Rare: incidence de 0,1%

Bilatéral: 10%, autres localisations

D>G

Calcification: 50%

♀>♂ (DFM)

40-60 ans

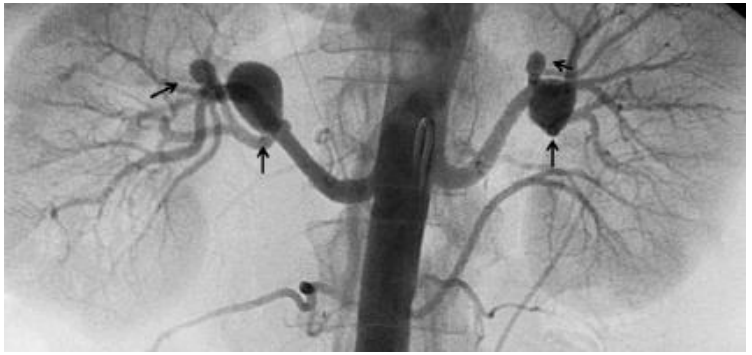

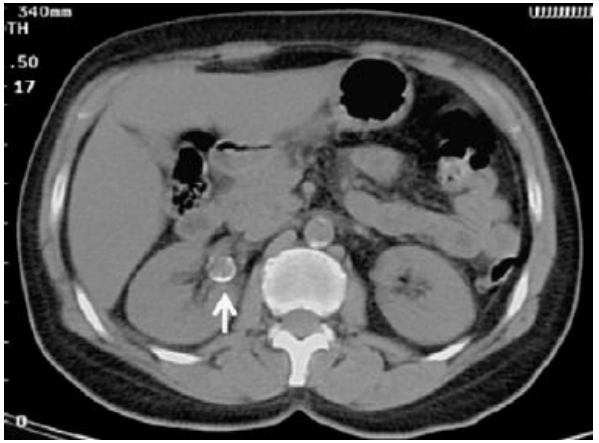

Clinical Imaging 35 (2011) 29–41

Etiologies

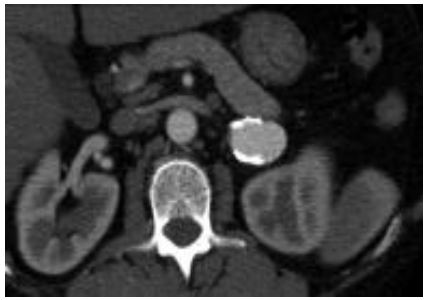

Athérosclérose

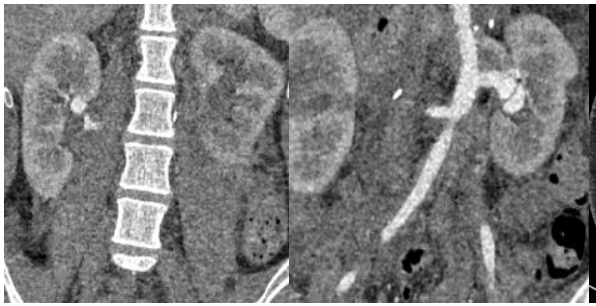

Congénitales

DFM

SED

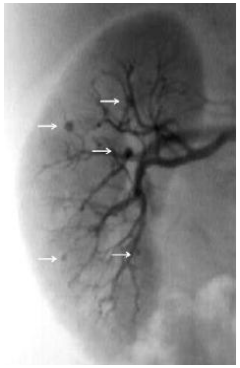

PAN

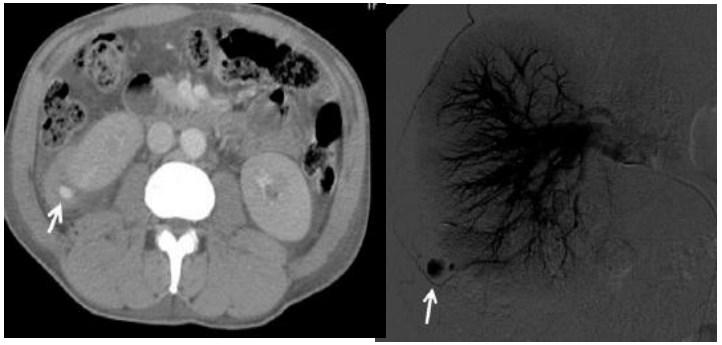

Iatrogènes

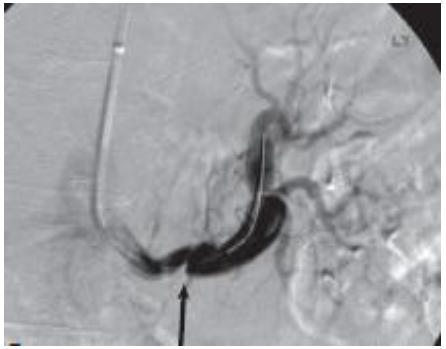

Dissections

Clinical Imaging 35 (2011) 29–41

Classification

90% extraparenchymateux

10% intraparenchymateux

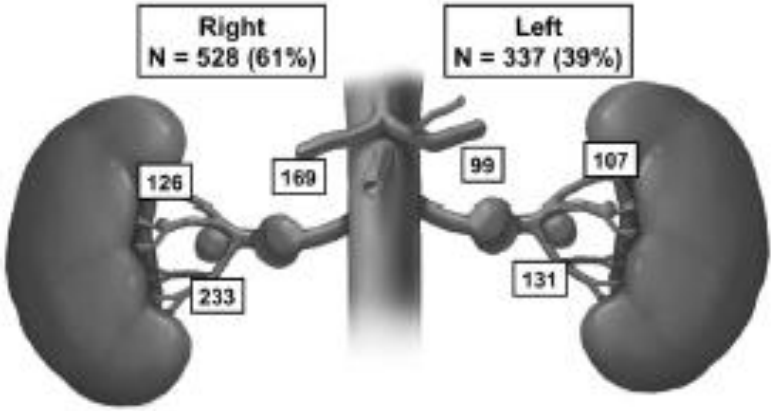

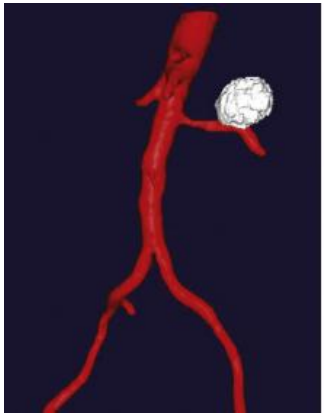

Sacciformes

>

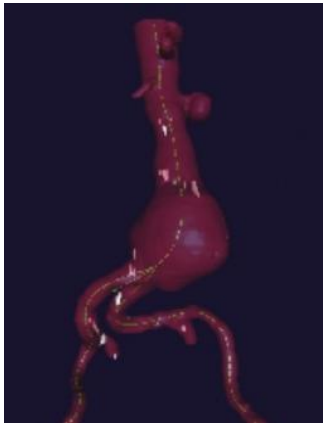

Fusiformes

J Vasc Surg 2014;-:1-7

Clinique

Asymptomatiques

Rupture

HTA (80%)

Douleurs

Hématurie

Dissection (phase aiguë)

Emboles distaux

Compression

Sténose (cause ou thrombus)

Indication

Taille: > 2cm → → 3cm (croissance: 0,086cm/an)

Femme jeune en âge de procréer

Maladie fibrodysplasique

HTA?

Rupture, douleurs, hématurie

Klausner et at., J Vasc Surg 2014

Traitement

Médical

Chirurgie conventionnelle

Endovasculaire

Chirurgie ouverte in situ

Anévrismorraphie – fermeture directe/ patch

Résection- anastomose
Pontage autologue (GVS/ AII) ou prothèse
Pontage spléno- ou hépato-rénal

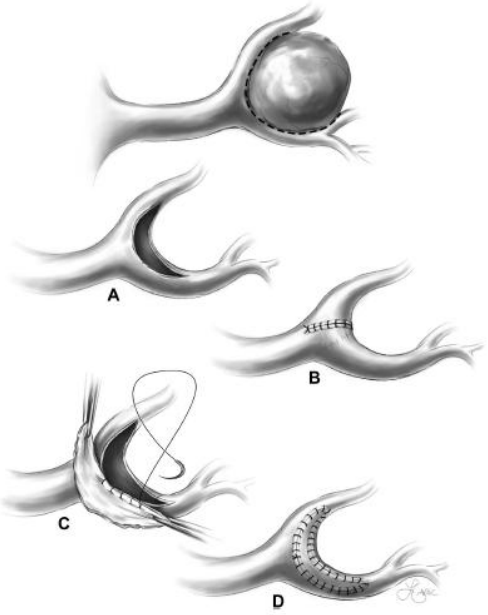

Fig 1. Following the longitudinal excision of a large saccular aneurysm located at the primary branch point (**A**), primary angioplastic closure of the defect in a transverse (Heinecke-Mikulicz) fashion (**B**) or patch angioplasty (**C** and **D**) may be considered.

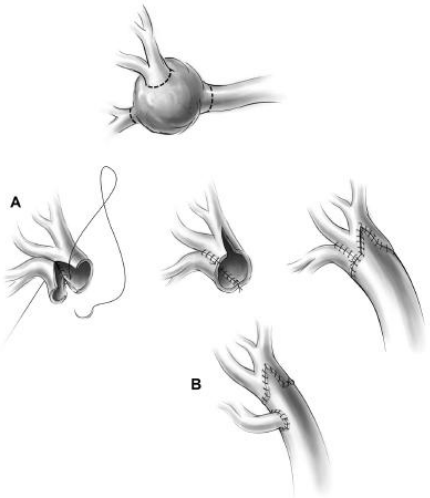

Fig 2. Aneurysms may have several outflow vessels of variable caliber. **A**, These vessels may be spatulated together to provide a common outflow target for a bypass graft; or **B**, branch vessels may require separate reimplantations onto the graft.

J Vasc Surg 2015;-:1-7

Chirurgie ouverte ex vivo

Plusieurs branches impliquées- intraparenchymateuse
Temps de clampage> 45 min, Echec endovasculaire

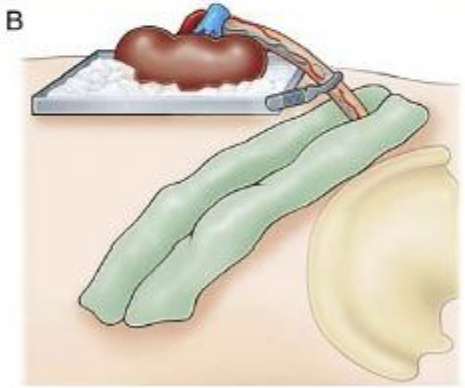

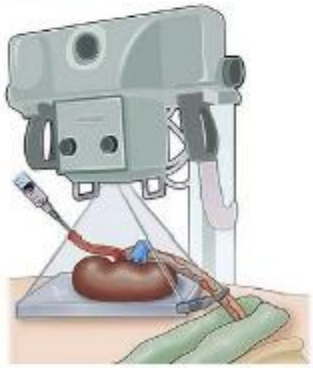

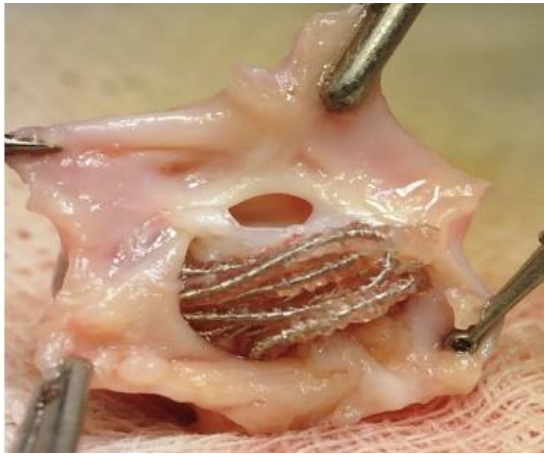

Eur J Vasc Endovasc Surg (2016) 51, 872e879

Traitement endovasculaire

Embolisation, coils, microcoils, liquide
Stent nu ou couvert

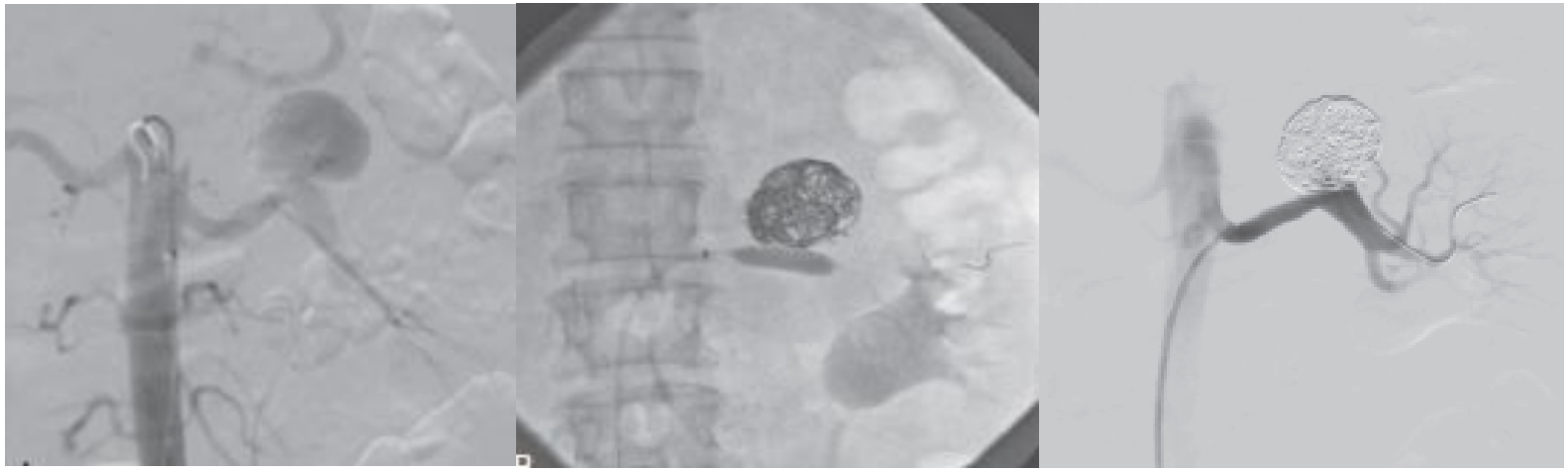

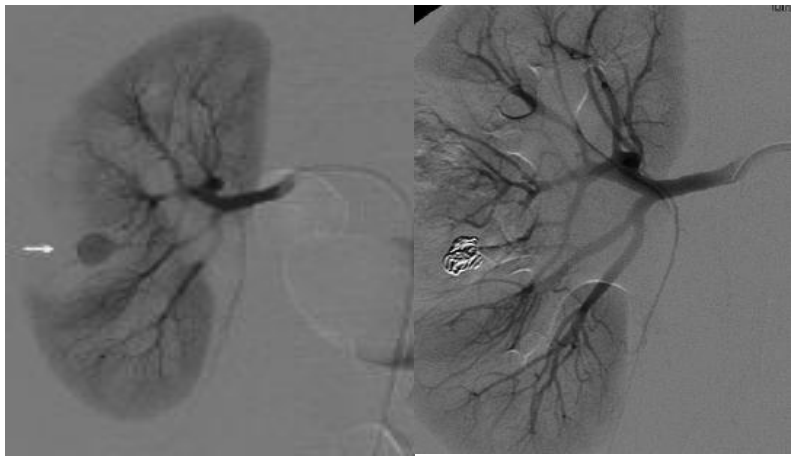

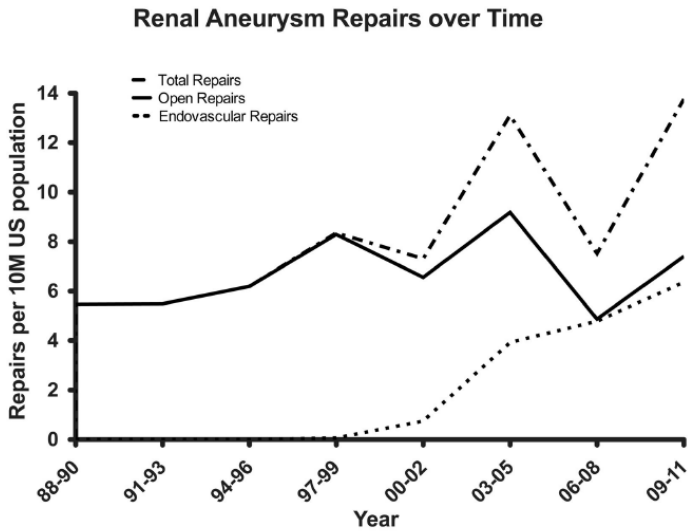

Wolek J, Endo treatment of renal Aneurysms; J *Vasc Surg. 2016 January ; 63(1): 77–81*

Résultats

Series	No.	Mean F/U, months	Approach	Morbidity	Secondary nephrectomy	Mortality	Primary patency	Vascular or renal reintervention
Hupp[17]	19/18	NR	IS N	'2 early occlusions' described	6%	0	89.5%	22%
Henke[7]	168/121	91	IS N	11.5%	21%	0	NR	5.8%
Pfeiffer[13]	94	46	IS	17%	0	0	75%-97%	6%
English[16]	84/62	47	IS N	12%	0	1.6%	93%-100%	0
Chandra[8]	10	10-12	IS EV	20%	0	0	NR	0
Robinson[12]	26/24	99	EV	11.5%	4%	0	94%	4%
Tsilimparis[15]	20	25	IS EV N	15%	5	0		10%
Morita[22]	29	NR	IS EV	56% 'long-term'	0	0	NR	14%
Klausner[9]	16/15	36	IS EV	20%	0	0	NR	0
Klausner[10]	168/149	NR	IS EV N	19% 'minor'/ 8% 'major'	3%	1.3%	NR	NR
Erezadi[23]	17	45	S Embo	NR	0	0		6%
Sédat[24]	15	38	S Embo (±balloon assist)	13%	0	0		13%
Zhang[25]	15	25	S Embo (±balloon assist)	60%	0	0		0
Tsilimparis	24	27	S Embo	17%	0	0		8%

Assist, Assistance; *EV*, ex vivo reconstruction; *Embo*, embolization; *F/U*, follow-up; *IS*, in situ reconstruction; *N*, planned nephrectomy; *No.*, number of patients / number of aneurysms if known and stated; *NR*, not reported; *S*, stent.

Mortalité quasi nulle

Table II. Summary of evidence on hypertensive outcomes following renal artery aneurysm (RAA) reconstruction

Series	No.[a]	Mean follow-up, months	Clinical improvement or cure in HTN
Martin[1]	14	4.8-7.8 years	76%
Hupp[17]	17 (8 patients described with 'refractory' HTN)	NR	100%
Henke[7]	40	94	60% taking fewer meds
Pfeiffer[13]	75	46	47%
English[16]	55	47	75%
Chandra[8]	7	11	Collective decrease in antihypertensive meds following surgery (1.6 vs 1.7; $P = .03$)
Robinson[12]	24	99	100% 82% with severe HTN taking fewer meds (1.[illegible] vs 2.6; $P = .0128$)
Klausner[9]	14	36	28%
Klausner[10]	76 described with 'difficult to control HTN'	NR	32% (no significant change in number of meds postoperatively)

HTN, Hypertension; *NR*, not recorded; *meds*, medications.
[a]Number of patients with HTN undergoing reconstruction.

Efficace sur l'HTA

Série prospective du service

Jan 2015 - Jan 2017
17 anévrismes disatux

Atherosclerosis: 8
DFM: 7
Congénital: 1
SED: 1

In situ

< 30 min de clampage

10 mois de suivi médian
Diam Moy: 17mm (9 – 29)
Pas de thrombose ni décès

Pas d'élévation de la créatinine
Bon résultat tensionnel

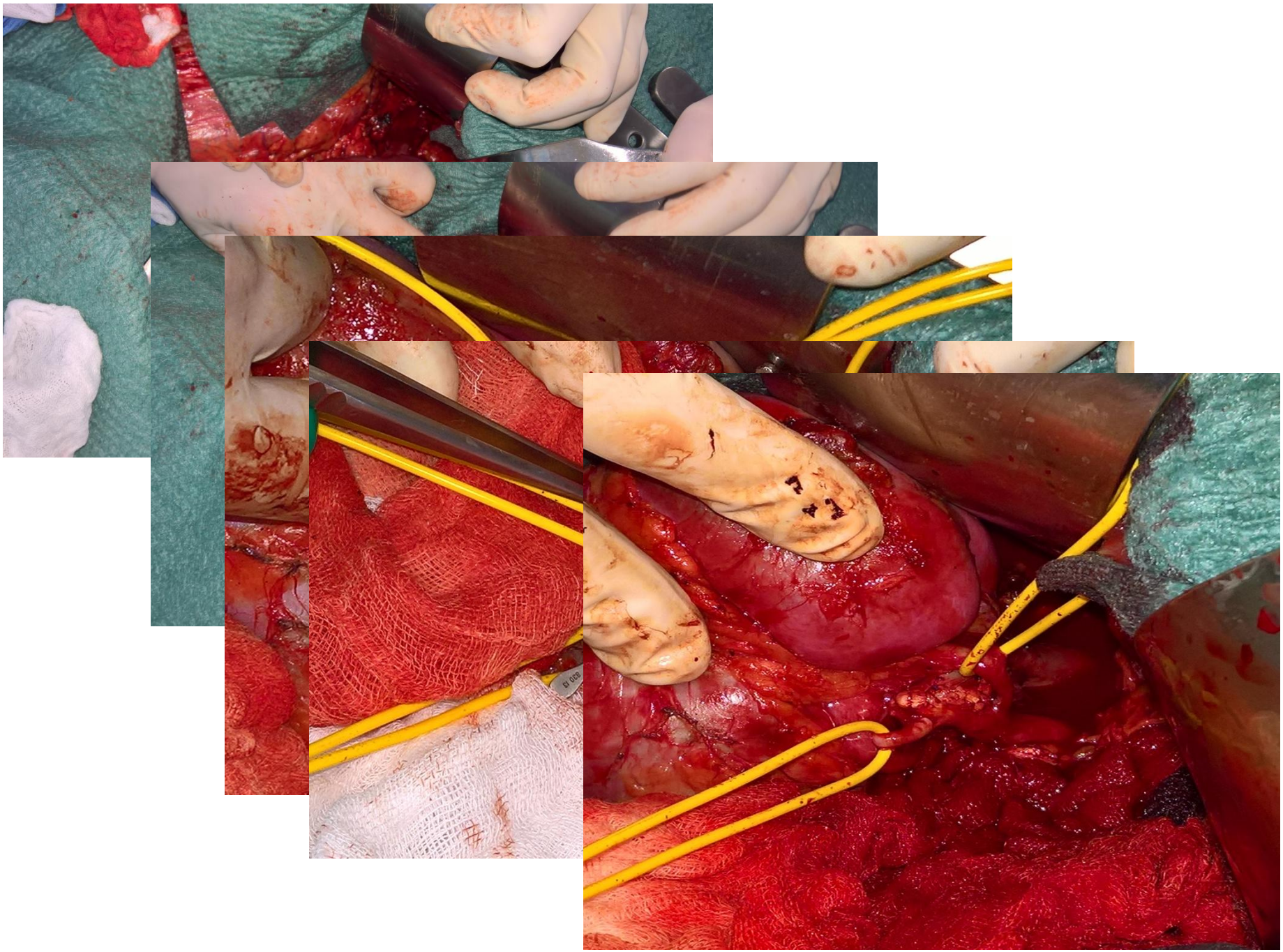

Conclusion

Entité rare, sous-diagnostiquée

Causes diverses

Le traitement médical à sa place

Le traitement chirurgical occasionne peu de morbidité et très peu de mortalité et est très durable. Notre expérience: la quasi-totalité des lésions peuvent être traitées par chirurgie in situ

Le traitement endovasculaire est un complément thérapeutique de la chirurgie